

## Cauda equina tumor mimicking an intradural disc herniation, with emphasis on differential diagnosis – a case report

S. KONISHI, H. NAKAMURA, M. KATO, H. TOYODA and M. DOZONO

Department of Orthopaedic Surgery, Osaka City General Hospital, 2-13-11 Miyakojimahondori Miyakojima-ku Osaka 534-0021, Japan

### Abstract

We report a rare case of lumbar disc prolapse with intradural schwannoma at the same level. A 33-year-old man had had moderate right leg pain for about four years, which had worsened suddenly when he lifted heavy baggage. MR imaging revealed lumbar disc prolapse at L4/5. An intradural tumor that was iso-intense on T1-weighted and slightly hyperintense on T2-weighted images was also recognized at the same level. The tumor was homogeneously enhanced on Gadolinium-MRI (Gd-MRI)

Intractable back and leg pain necessitated surgical treatment, which yielded a definitive diagnosis of the intradural tumor as schwannoma on histological examination. The intractable pain disappeared immediately after surgery. The patient's intractable and prolonged pain appeared to be due to combined compression by the intradural tumor and disc prolapse. The findings of Gadolinium-MRI were helpful in making the diagnosis.

**Key words :** Lumbar spine, disc, cauda equina, schwannoma, MRI.

### Introduction

Lumbar disc prolapse is one of the most common causes of low back and leg pain, and can easily be diagnosed with MRI. When an intradural mass is observed in a patient with lumbar disc prolapse, the most likely diagnosis is intradural disc herniation. Intradural disc herniations comprise 0.26-0.30% of all cases of disc herniation, and 92% exist in the lumbar spine. They are most commonly observed at L4/5 level (Kataoka *et al.*, 1989 ; Connolly *et al.*, 1997).

On the other hand, schwannoma is the most common intradural extramedullary spinal cord tumor (Cervoni *et al.*, 1995 ; Wipplid *et al.*, 1997). When it develops at the level of the cauda equina, it can cause severe low back and leg pain. However, it is sometimes asymptomatic due to its slowly progressive nature and is detected incidentally on MRI examination.

We recently experienced a rare case of lumbar disc prolapse with intradural schwannoma at the

same level. The patient had complained of moderate leg pain for a long period of time, although the pain had suddenly worsened when he lifted heavy luggage. His intractable and prolonged pain appeared to be due to combined compression by the intradural tumor and disc prolapse. The purpose of this paper is to report details of this rare case and describe differentiation of cauda equina tumor from intradural disc herniation.

### Case report

A 33-year-old man presenting with intractable low back and leg pain was referred to our clinic. He had had moderate right leg pain for about four years, which had worsened suddenly when he lifted heavy luggage two months before his visit to our clinic. Physical examination at the time of admission revealed restricted motion on the Straight Leg Raising (SLR) test, mild weakness of the tibialis anterior and extensor hallucis longus, and sensory disturbance along the distribution of the L5 nerve root on the right side. MR imaging revealed lumbar disc prolapse at L4/5. An intradural tumor that was isointense on T1-weighted and slightly hyperintense on T2-weighted images was also recognized at the same level. The tumor was enhanced homogeneously on Gadolinium-MRI (Gd-MRI) (Fig. 1). CT discography demonstrated leakage of contrast medium into the epidural space, indicating transligamentous disc prolapse, without extension into the intradural space (Fig. 2). At the time of discography, the patient complained of reproduction of his leg pain.

Because the patient's intractable pain persisted despite conservative treatment, surgical treatment was performed. Following hemilaminectomy of left L4 and L5 and incision of the dural sac, a tumor with a yellow surface was recognized. Given the possibility of damage to the nerve root by retraction, in the first stage the intradural tumor was resected with the posterior ramus of the nerve root of origin after separation of adhesions around the cauda equina (Fig. 3). Then, following suturing of

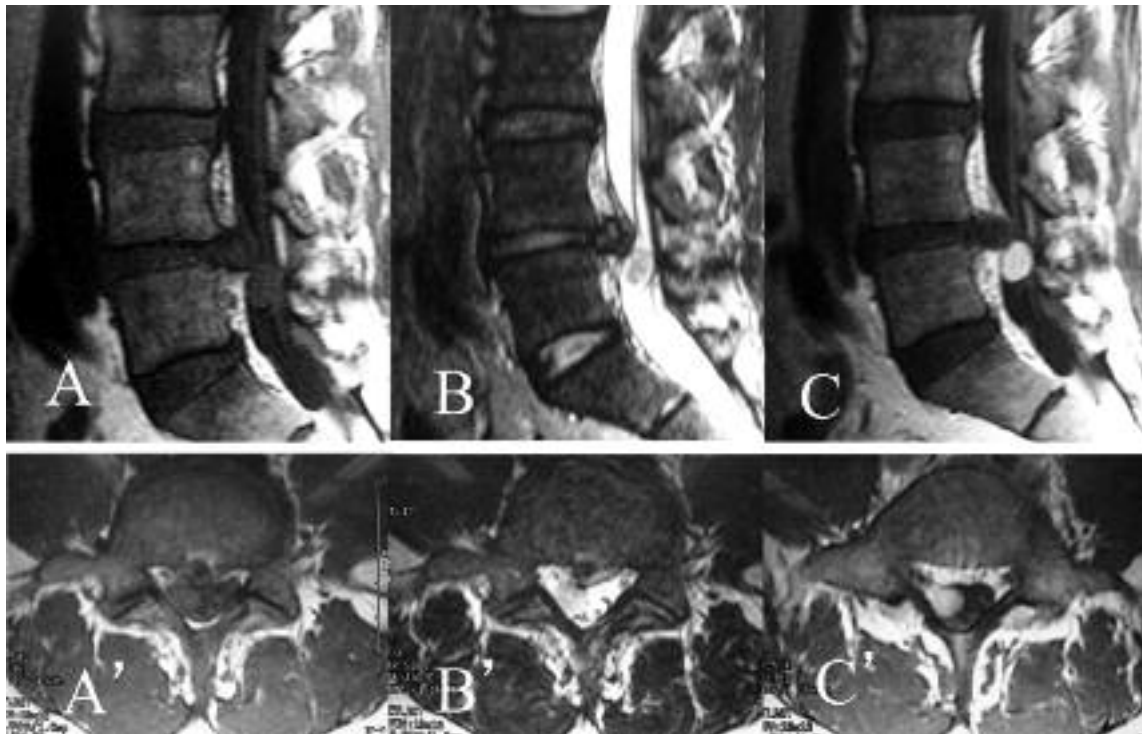


FIG. 1. — Left column : T1-weighted images, middle column : T2-weighted images, right column : Gd-enhanced images. A mass isointense on T1-weighted images and slightly hyperintense on T2-weighted images is observed in combination with L4/5 disc prolapse. The mass is homogeneously enhanced on Gd-MRI and does not appear to be connected to the disc prolapse shadow.

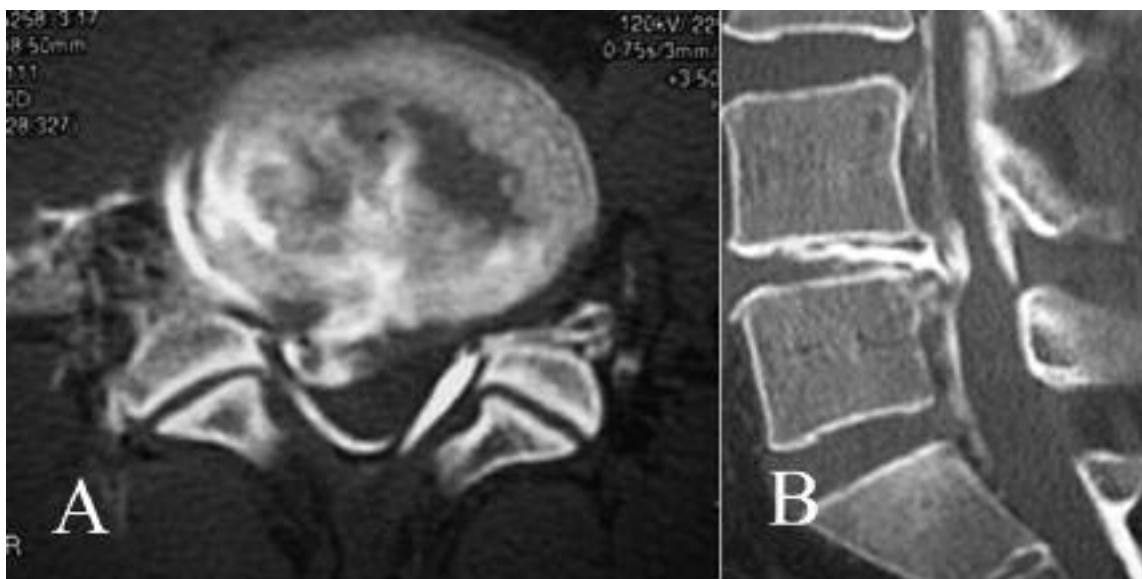


FIG. 2. — CT after discography reveals leakage of contrast medium into the epidural space but not the intradural space

the incised dural sac, the prolapsed disc was curetted after retraction of the nerve root. The prolapsed disc was tightly adherent to the dural sac, but did not penetrate the membrane. Histological examination of the tumor demonstrated typical findings of schwannoma of Antoni type B. Recovery from surgery was uneventful, and the intractable pain disappeared immediately after surgery. At five years after surgery, the patient remains pain-free and his motor weakness has completely resolved.

### Discussion

Intradural masses are now easily detected with MRI. When an intradural mass is observed together with lumbar disc prolapse, intradural lumbar disc herniation can be considered one of the most likely diagnoses.

Intradural disc herniations comprise 0.26-0.3% of all disc herniations (Neogovetic *et al.*, 2001), and are most frequently observed in the lumbar region

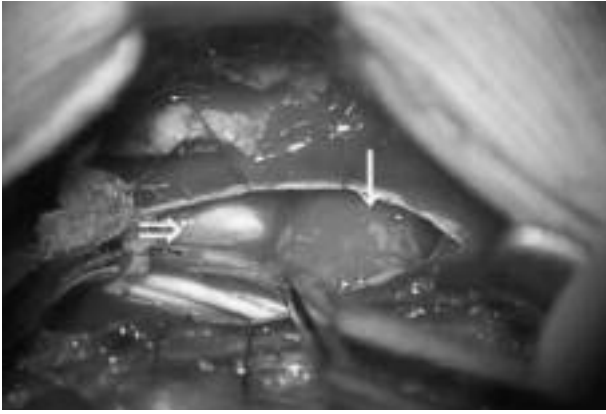


FIG. 3 — Tumor (arrow) exists in the ventral portion within the dural sac. Indentation of the ventral dural sac by prolapsed disc (open arrow) can be observed.

(Iwamura *et al.*, 2001). Firm attachment of the posterior longitudinal ligament to the ventral dura induces adhesions in this region in the case of lumbar disc prolapse, and this can predispose to intradural disc prolapse. L4/5 has been reported to be the most frequent location of intradural disc herniation due to the above-noted anatomical features.

On MRI, intradural disc herniation exhibits intermediate signal intensity on T1-weighted images and low signal intensity on T2 weighted images, as well as peripheral enhancement on Gd-MRI (D'Andrea *et al.*, 2001 ; Lee *et al.*, 2006). In some cases, T2-weighted imaging demonstrates increased signal intensity (Holtas *et al.*, 1987 ; Aydin *et al.*, 2004).

Cauda equina tumors have been reported to comprise about 6% of all spinal cord tumors (Fearnside *et al.*, 1987). Although these lesions can cause low back or leg pain, they are sometimes asymptomatic due to their slowly progressive nature (Shimada *et al.*, 2006). Among cauda equina tumors, schwannoma and meningioma are most frequent. The most common feature of schwannoma on MRI is isointensity on T1-weighted images and high-intensity change on T2-weighted images. On the other hand, meningiomas are isointense with spinal cord on T1-weighted images, and the majority are isointense on T2-weighted images (Sato *et al.*, 1997). These lesions demonstrate prominent enhancement throughout on Gd-MRI, except for schwannoma, which exhibits central cystic degeneration.

In the present case, the intradural mass was isointense on T1-weighted and slightly hyperintense on T2-weighted images and exhibited marked homogeneous enhancement on Gd-MRI. Based on these findings, lumbar disc prolapse combined with cauda equina schwannoma was strongly suspected. In addition, the findings of CT discography were helpful in ruling out intradural disc herniation.

In the present patient, the tumor originated from the posterior ramus of the L5 nerve root. Co-existence of lumbar disc prolapse and a nerve root tumor at the same level is extremely rare. Albert reported a case of coexistence of lumbar disc prolapse and intradural schwannoma (Albert *et al.*, 1988). However, the present case is to our knowledge the first of coexistence of these lesions in the English literature since MRI became available.

We suspected that the patient's prolonged, moderate leg pain was due to the intradural neurinoma, while his severe leg pain of sudden onset was due to additional compression by disc prolapse. Despite the transligamentous nature of disc prolapse, which has been reported to undergo resorption (Ozaki *et al.*, 1999), the patient's severe pain persisted with application of various types of conservative treatment. Resection of both the prolapsed disc and neurinoma yielded a satisfactory surgical outcome.

During the operation, there was the potential for injury to the nerve root with retraction, since the tumor compressed the nerve root from inside of the dural sac. Careful resection of the tumor followed by discectomy was therefore considered preferable for prevention of nerve root injury.

In summary, combined compression by lumbar disc prolapse and intradural neurinoma produced intractable and prolonged low back and leg pain, and resection of both the prolapsed lumbar disc and the intradural schwannoma yielded a satisfactory outcome. In differentiation of the intradural schwannoma from intradural disc herniation preoperatively, Gd-MRI was helpful as a non-invasive diagnostic modality.

Hiroaki NAKAMURA, M.D.,  
 Chief Director and Clinical Professor,  
 Department of Orthopaedic Surgery,  
 Osaka City General Hospital,  
 2-13-22 Miyakojimahondori Miyakojima-ku  
 Osaka 534-0021 (Japan).  
 E-mail : hnakamura@med.osaka-cu.ac.jp